

MI Paste Plus to prevent demineralization in orthodontic patients: A prospective randomized controlled trial

Michael A. Robertson,^a Chung How Kau,^b Jeryl D. English,^c Robert P. Lee,^d John Powers,^e and Jennifer T. Nguyen^f

Houston, Tex, Birmingham, Ala, and Ann Arbor, Mich

Introduction: Enamel demineralization is a problem in orthodontics. Fluoride is partially effective in addressing this problem, but additional treatment options are needed. The objective of this prospective randomized controlled trial was to determine the effectiveness of a new product, MI Paste Plus (GC America, Alsip, Ill), in the prevention or reduction of white spot lesions in orthodontic patients. **Methods:** Sixty patients who were undergoing routine orthodontic treatment were recruited for this prospective randomized clinical trial. A double-blind method of randomization was used to determine whether each patient received the MI Paste Plus or a placebo paste (Tom's of Maine, Salisbury, United Kingdom). Each patient was asked to administer the paste by using a fluoride tray for a minimum of 3 to 5 minutes each day at night after brushing. Photographic records obtained in a light-controlled environment were used to record the presence or absence of white spot lesions in both groups. The enamel decalcification index was used to determine the number of white spot lesions per surface at each time interval. Patients were followed at 4-week intervals for 3 months. A scoring system from 0 to 6 was used to determine the level of caries or cavitations. This system was also used for each tooth at each time interval. **Results:** Fifty patients (26 using MI Paste Plus, 24 using the placebo paste) completed the study. The enamel decalcification index scores for all surfaces were 271 and 135 at the start of treatment and 126 and 258 at the end of treatment for the MI Paste Plus and placebo paste groups, respectively. The enamel decalcification index scores in the MI Paste Plus group reduced by 53.5%, whereas the placebo group increased by 91.1% during the study period. A 3-way analysis of variance (ANOVA) was done for the average enamel decalcification index scores. The surface type, the product/time interactions, and the product/surface interactions of the mean enamel decalcification index scores were significant ($P < 0.05$). **Conclusions:** MI Paste Plus helped prevent the development of new white spot lesions during orthodontic treatment and decreased the number of white spot lesions already present. The placebo paste had no preventive action on white spot development during orthodontic treatment; the number of lesions actually increased. MI Paste Plus reduced white spots on the gingival surfaces; the placebo paste had the opposite effect. The incisal surface effect on the mean enamel decalcification index scores over time and between products was highly significant. The incisal enamel decalcification index scores were consistently higher than those for the other surfaces (mesial, distal, and gingival). (Am J Orthod Dentofacial Orthop 2011;140:660-8)

Enamel decalcification, or white spot lesion formation, is a phenomenon that occurs primarily on the smooth enamel surfaces of teeth, notably in the gingival third of the crown.¹ Demineralized enamel, the precursor to caries formation, can be attributed to

fixed orthodontic appliances² and prolonged exposure to bacterial plaque.³ Bacterial plaque promotes the accumulation of acidic by-products and demineralization that leads to successive changes in the optical properties of subsurface demineralized enamel. The progression

^aFormer resident, Department of Orthodontics, University of Texas Health Science Center at Houston.

^bProfessor and chairman, Department of Orthodontics, University of Alabama at Birmingham.

^cChairman and program director, Department of Orthodontics, University of Texas Health Science Center at Houston.

^dClinical associate professor, Department of Orthodontics, University of Texas Health Science Center at Houston.

^eEditor, The Dental Advisor, Ann Arbor Michigan.

^fResearch assistant, Department of Orthodontics, University of Texas Health Science Center at Houston.

The authors report no commercial, proprietary, or financial interest in the products or companies described in this article.

Reprint requests to: Chung How Kau, Department of Orthodontics, University of Alabama at Birmingham, 1919 7th Ave S, SDB 305, Birmingham, AL 35294; e-mail, ckau@uab.edu.

Submitted, March 2010; revised and accepted, October 2010.
0889-5406/\$36.00

Copyright © 2011 by the American Association of Orthodontists.
doi:10.1016/j.ajodo.2010.10.025

to clinically detectable white spot lesions can occur as early as 1 month after the placement of orthodontic appliances.⁴⁻⁶

Over the past 30 years, several studies have reported increases in white spot lesions after orthodontic treatment.⁶⁻⁹ Although a large portion of the nonorthodontically treated population experiences some form of decalcification, orthodontic patients have shown increases in both new lesions and the severity of preexisting enamel opacities.⁴⁻⁸ Approximately 50% of orthodontic patients develop white spot lesions in at least 1 tooth, compared with only 24% in those not undergoing orthodontic treatment.⁶⁻⁹

Appliance removal halts white spot formation, and further elimination of cariogenic factors through diligent oral hygiene efforts inactivates incipient lesions, which might regress over time.¹⁰⁻¹² Complete elimination of lesions is unlikely because of the rapid remineralization of the enamel surface with a high concentration of fluorides, which restrict the passage of ions into the deeper, more affected layers. Therefore, immediate application of a high concentration of fluoride is not recommended. There might be fewer enamel discolorations with time because of further remineralization, but regression is primarily credited to gradual surface abrasion of the tooth structure.¹⁰

Such problems with enamel decalcification in orthodontic patients have caused clinicians to search for a solution to orthodontic-associated demineralization. Because fluoride treatment immediately upon debonding is not advocated, clinicians have proposed fluoride treatment and fluoride-releasing materials at the commencement of therapy.¹⁴ Recommendations include oral hygiene instructions and reinforcement; fluoridated toothpastes, varnishes, and mouthwashes; and fluoridated water supplies. Lack of patient compliance hinders these efforts.¹³⁻¹⁶

A new product, MI Paste Plus (GC America, Alsip, Ill), is currently available and has been shown in some initial reports to be useful in the reduction of white spot lesions. Although MI Paste Plus does not remove the need for compliance, it is hoped that it provides a new way to prevent and resolve decalcifications that develop during orthodontic treatment. MI Paste Plus reportedly restores minerals to the teeth and helps to stimulate saliva production. It contains casein phosphopeptide-amorphous calcium phosphate, a special milk-derived protein that is potentially a breakthrough in oral health care in helping to remineralize teeth. More specifically, casein phosphopeptide is produced from digestion of the milk protein casein by aggregation with calcium phosphate and purification by ultrafiltration. The casein phosphopeptide stabilizes the amorphous calcium

phosphate in solution, maintaining high concentration gradients of calcium and phosphate in the white spot lesion, thus effecting high rates of enamel remineralization.

The aim of this study was to determine whether MI Paste Plus has an effect on the formation and resolution of white spot lesions in patients undergoing orthodontic treatment. It is believed to provide a new way to reduce and prevent the decalcifications that develop during orthodontic treatment.

MATERIAL AND METHODS

The study protocol was reviewed and approved by the institutional review board of the University of Texas Health Science Center at Houston.

Sixty from a possible 65 patients who were undergoing routine orthodontic treatment were recruited for this prospective double-blind randomized clinical trial. The patients were 12 years of age and older. A caries risk assessment was used to determine their caries risks. They were carefully selected for the study and included and excluded on the following criteria. The inclusion criteria were patients (1) with permanent dentition, (2) who would be compliant with using the paste (in the investigator's opinion), (3) who had not extensively used fluoride regimens, and (4) who were 12 years of age and older. The exclusion criteria were patients (1) with any medical or dental condition that (in the investigator's opinion) could impact the study results during its expected length, (2) currently using any investigational drug, (3) who planned to move within 6 months of enrollment, (4) who had received or were currently receiving fluoride treatment for white spot lesions, and (5) who had an allergy to IgE casein.

The patients were recruited through the Orthodontic Postgraduate Clinic at the University of Texas Health Science Center Dental Branch at Houston. Sixty-five patients who expressed an interest in the study were approached to participate. Five did not want to participate for a variety of reasons after protocol procedures were explained and did not sign the consent form. Sixty patients agreed to participate in the study. A study administrator prepared the pastes and assigned the randomizations. The process of randomization was carried out by drawing the letters X and Y from a prepared pool of letters (X was the placebo [Tom's of Maine, Salisbury, United Kingdom], and Y was the MI Paste Plus). The assigned X and Y pastes were given to a clinician to administer to the patients.

The paste was delivered in a prefabricated fluoride varnish tray and used once daily for 3 months. Patients placed the tray with the paste into the mouth and left

it for 3 to 5 minutes after they had already brushed their teeth at night. The patients were asked to expectorate and not to rinse their mouth, eat, or drink after using the paste. Patients were reviewed every 4 weeks. During the recall period, photographic records and clinical examinations were carried out.

Photographic records were used to determine the presence of the white spot lesions in the study groups from the left first premolar to the right first premolar in both the mandible and the maxilla. A standard intraoral photographic camera was used, the photographs were taken in a light-controlled environment, and the photographs were captured with a preset protocol. The enamel decalcification index score (Banks and Richmond¹⁷) was used to determine the number of white spot lesions at each time point (Fig 1). The 4 time points were start of treatment (T1), 4 weeks into treatment (T2), 8 weeks into treatment (T3), and 12 weeks into treatment (T4).

The international caries detection and assessment system was used for the clinical examinations; this is a visually based system. Only primary caries detection was used for the labial surfaces of the teeth. Essentially, a scoring system from 0 to 6 was used in determining the level of caries (Table I).

Statistical analysis

Three-way analysis of variance (ANOVA) (StatView; SAS Institute, Cary, NC) was used to analyze the enamel decalcification index scores of the maxillary and mandibular right first premolars to the left first premolars at the 0.05 level of significance. Two-way ANOVA was used to analyze the international caries detection and assessment system scores. Fisher protected least significant difference intervals were used to compare mean enamel decalcification index scores.

The enamel decalcification index and the international caries detection and assessment system scores were randomly recorded for 5 sets of patients at the start and end of treatment. Three operators (M.A.R., J.T.N., C.H.K.) scored the photographs independently. Their scores were compared by using the *t* test; no statistically significant difference ($P \geq 0.05$) was found between the operators.

RESULTS

This study was a prospective clinical trial with a double blind method of randomization. We found that MI Paste Plus, used as presented here, not only lessened the occurrence of white spots, but also actually reduced the number of white spots already present. The results of the statistical analysis are presented in Table II, and the reduction in scores in Tables III and IV.

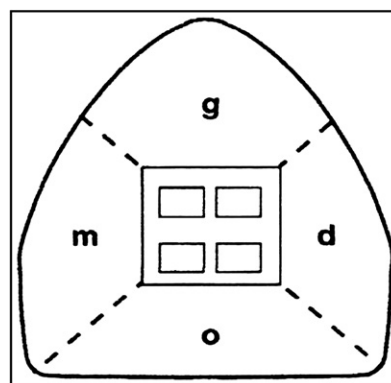


Fig 1. Enamel decalcification index. The facial surface of each tooth was divided into 4 areas. A score was allocated for each area of each tooth: 0, no decalcification, to 3, decalcifications covering 100% of the area. *m*, Mesial; *g*, gingival; *d*, distal; *o*, occlusal.

Table I. International caries detection and assessment system (ICDAS) scoring (each tooth has its own score based on how affected or broken down the tooth was from decalcification or caries)

ICDAS detection	ICDAS lay terms	ICDAS dental terms
6	Severe decay	Extensive cavity with visible dentin
5	Severe decay	Distinct cavity with visible dentin
4	Established decay	Underlying dentin shadow
3	Established decay	Localized enamel breakdown
2	Early stage decay	Distinct visual change in enamel
1	Early stage decay	First visual change in enamel
0	Sound	Sound

The subjects were recruited over a 1-year period. Sixty-five patients who expressed an interest were approached to participate. Five did not want to participate for a variety of reasons after protocol procedures were explained and did not sign the consent form. Sixty patients participated in the study. Of the 29 patients, chosen randomly from the 60, who used the MI Paste Plus, 26 completed the study; of the 31 placebo patients, 24 completed the study. This amounted to 416 teeth and 1664 tooth surfaces studied for the MI Paste Plus patients, and 384 teeth and 1536 tooth surfaces studied for the placebo patients.

There was a decrease of 53.5% in the enamel decalcification index scores with MI Paste Plus usage from T1 to T4 (Table III). Moreover, the sums of the enamel decalcification index scores for all teeth in the MI Paste Plus group were 271 at T1 and 126 at T4 (Table III).

Table II. ANOVA table for average enamel decalcification index scores

	P value	Power
Product	0.61	0.080
Time	0.99	0.058
Surface	<0.0001	1.000
Product/time interaction	0.0003	0.977
Product/surface interaction	0.03	0.696
Time/surface interaction	1.00	0.086
Product/time/surface interaction	0.97	0.166

Table III. Enamel decalcification index (EDI) scores for tooth surfaces of all teeth exposed to MI Paste Plus at T1 and T4

Surface	Sum of EDI at T1	Sum of EDI at T4	Change in EDI, T1-T4 (%)
All 4 surfaces	271	126	-53.5
Mesial	54	20	-63.0
Distal	58	20	-65.5
Gingival	38	21	-44.7
Incisal	121	65	-46.3

The patients in the placebo group, on the other hand, showed a 91.1% increase in enamel decalcification index scores from T1 to T4 (Table IV). More specifically, the sums of the enamel decalcification index scores for all teeth in the placebo group were 135 at T1 and 258 at T4 (Table IV).

Consistent with the enamel decalcification index scores, MI Paste Plus was linked to a 44.8% decrease in scores over the same time period (Table V). Moreover, the sums of the international caries detection and assessment system scores for all teeth in the MI Paste Plus group were 145 at T1 and 80 at T4 (Table V). Also consistent with the enamel decalcification index scores, the placebo corresponded with an increase of 43.1% in the international caries detection and assessment system over the same time period (Table V). More specifically, the sums of the international caries detection and assessment system scores for all teeth in the placebo group were 116 at T1 and 166 at T4 (Table V).

A 3-way ANOVA (Table II) and the Fisher protected least significant difference for average enamel decalcification index scores (significance level, 5%) were used to analyze the average enamel decalcification index scores. The surface type, the product/time interactions, and the product/surface interactions were proven significant ($P < 0.05$). For example, it was significant that the mean enamel decalcification index scores for each surface (gingival, mesial, distal, and incisal) decreased steadily in the MI Paste Plus group and

Table IV. Enamel decalcification index (EDI) scores for tooth surfaces of all teeth exposed to the placebo at T1 and T4

Surface	Sum of EDI at T1	Sum of EDI at T4	Change in EDI, T1-T4 (%)
All 4 surfaces	135	258	+91.1
Mesial	18	29	+61.1
Distal	10	32	+220.0
Gingival	23	60	+160.9
Incisal	84	137	+63.1

Table V. International caries detection and assessment system (ICDAS) scores for all teeth at all time points

Product	Sum of ICDAS scores for all teeth				Change in ICDAS, T1-T4 (%)
	T1	T2	T3	T4	
MI Paste Plus	145	129	95	80	-44.8
Placebo	116	145	150	166	+43.1

increased for each surface in the placebo group from T1 to T4. Time, no doubt, helped the MI Paste Plus to remineralize the white spots and did nothing for the placebo group to prevent decalcification.

For the MI Paste Plus and the placebo groups, at every time point, the incisal edge average enamel decalcification index scores differed significantly with each of the other surfaces (mesial, distal, and gingival) individually. In addition, even though the incisal edge mean enamel decalcification index scores for both groups changed the least with respect to percentages, of all the surfaces from T1 to T4, it was by far the surface with the most cumulative enamel decalcification index points at each time point and for both products. Therefore, the incisal edges of the studied teeth, whether subjected to the placebo or the MI Paste Plus, had the most white spots of any of the 4 surfaces for the time period they were observed.

The largest actual percentage change for a surface in the average enamel decalcification index score from T1 to T4 for the MI Paste Plus group was for the distal surface, with a 65.5% decrease, followed by a decrease of 63.0% for the mesial surface (Table III). The largest change for the placebo group over the same time period was for the distal surface (+220%), followed by the gingival surface (+160.9%) (Table IV). Figure 2 shows that after T1 the gingival surfaces of the MI Paste Plus sample had lower mean enamel decalcification index scores than did the gingival surfaces of the placebo. The placebo, it seems, allowed more white spots to form

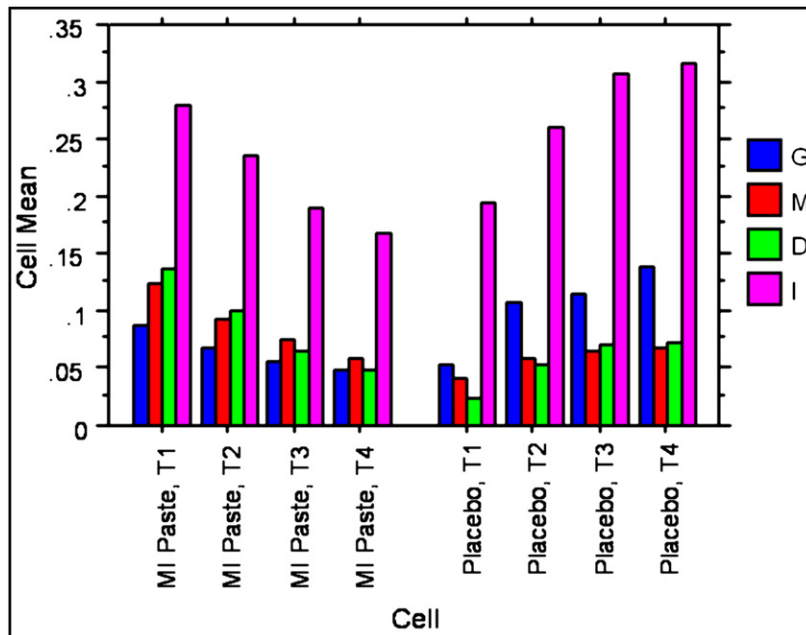


Fig 2. Interaction bar plot for average enamel decalcification index scores and the effect of the interaction of product/time/surface. *g*, Gingival; *m*, mesial; *d*, distal; *i*, incisal.

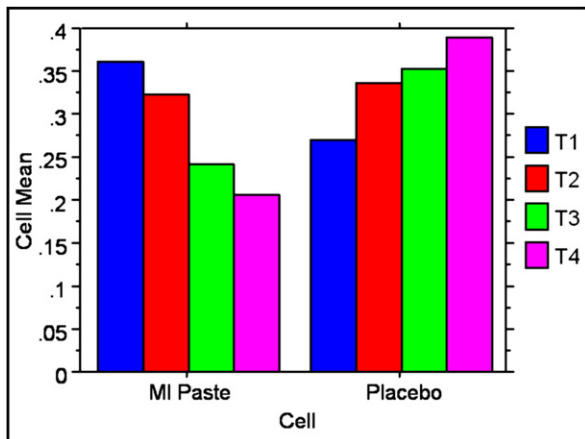


Fig 3. Interaction bar plot for average international caries detection and assessment system scores and the effect of the interaction of product/time.

in the gingival quadrant than did the MI Paste Plus, which actually reduced the white spots in this same quadrant.

A 2-way ANOVA was done for the average international caries detection and assessment system scores. A bar plot for these scores in Figure 3 shows a steady decrease with each time interval in the international caries detection and assessment system scores for the MI Paste

Plus and a steady increase for the placebo, although these effects were not statistically significant. This trend correlates well with the enamel decalcification index scores.

DISCUSSION

White spot lesion formation is frequently encountered in orthodontic patients.⁴⁻⁹ The roles of dental materials, such as glass ionomer and resin sealants, in inhibiting demineralization have been well documented and are well accepted as a standard of care. The benefit of topical fluoride in reducing demineralization and supporting remineralization is well recognized. Considerable research has been devoted to fluoride delivery methods that reduce or minimize enamel demineralization in orthodontic patients.^{4,13,15,16,18-31} Despite the availability of various fluoride delivery protocols for orthodontic patients, they often fail to comply with their practitioners' recommendations. There have also been concerns about the use of fluorides in dentistry. The risks are minimal, but these concerns have caused some countries not to add fluorides to the drinking water.

In this study, an alternative method for the prevention of white spot lesions was carried out. In this prospective double blind randomized controlled clinical trial, the effects of the casein phosphopeptide-amorphous calcium phosphate in MI Paste Plus were studied. This study showed that MI Paste Plus, used as

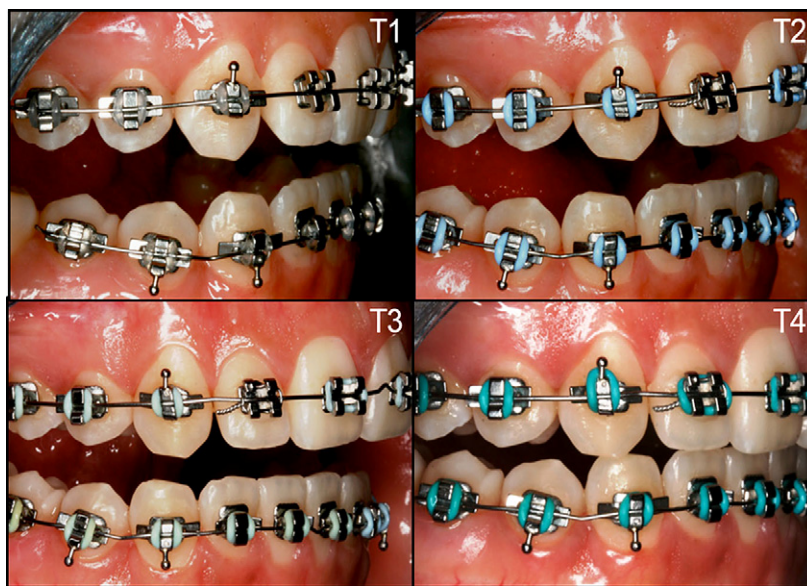


Fig 4. Right buccal intraoral photographs of a patient from T1 to T4 using the MI Paste Plus.

presented here, not only prevents white spots, but also reduces the number of white spots already present, as shown in the intraoral clinical pictures of a patient using MI Paste Plus in Figures 4, 5, and 6.

Table II also shows that the 2 products did not behave the same over time. MI Paste Plus' enamel decalcification index scores for each surface decreased for each time period, while the placebo's increased, as shown in Figure 2. Moreover, the sum of the enamel decalcification index scores for all teeth for MI Paste Plus was 271 at T1, and it decreased to 126 by T4 (Table III). The placebo, over the same time period, went from 135 to 258 (Table IV). The placebo, therefore, did not help to resolve or halt white spot formation. Figure 7 shows clinical intraoral photographs of a patient using the placebo for a 3-month period, illustrating the lack of improvement of white spots, even with exemplary oral hygiene. Figure 8 shows intraoral photographs of a different patient whose white spots worsened over time while using the placebo.

From T1 to T4, all surfaces (gingival, mesial, distal, and incisal) showed a significant decrease in mean enamel decalcification index scores with MI Paste Plus (Table III). Furthermore, there were decreases of 53.5% in mean enamel decalcification index scores and 44.8% in mean international caries detection and assessment system scores (Table V) for all teeth together with MI Paste Plus usage from T1 to T4 (Table III). The placebo, on the other hand, showed a 91.1% increase in mean enamel decalcification index scores (Table IV) and an increase of 43.1% in the international caries

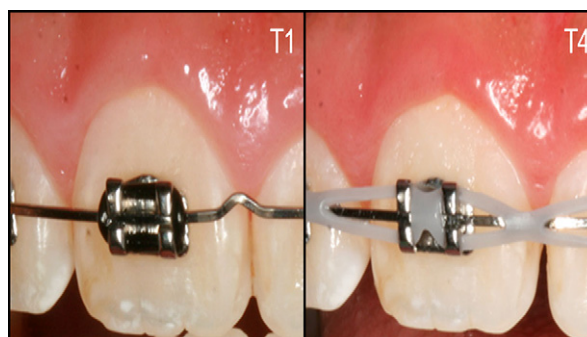


Fig 5. Intraoral photographs of the maxillary right central incisor of a patient at T1 and T4 using the MI Paste Plus.

detection and assessment system (Table V) for all teeth together over the 3-month period of the study, further demonstrating a rise in decalcifications with the placebo. There seemed to be a strong correlation between the enamel decalcification index and the international caries detection and assessment system scores. As the average enamel decalcification index scores slowly decreased for the MI Paste Plus, so did the international caries detection and assessment system scores. Likewise, as average enamel decalcification index scores slowly increased for the placebo, and so did the international caries detection and assessment system scores. All international caries detection and assessment system results, however, were not significant (Table VI). Perhaps if more patients had been studied, there might have been a greater

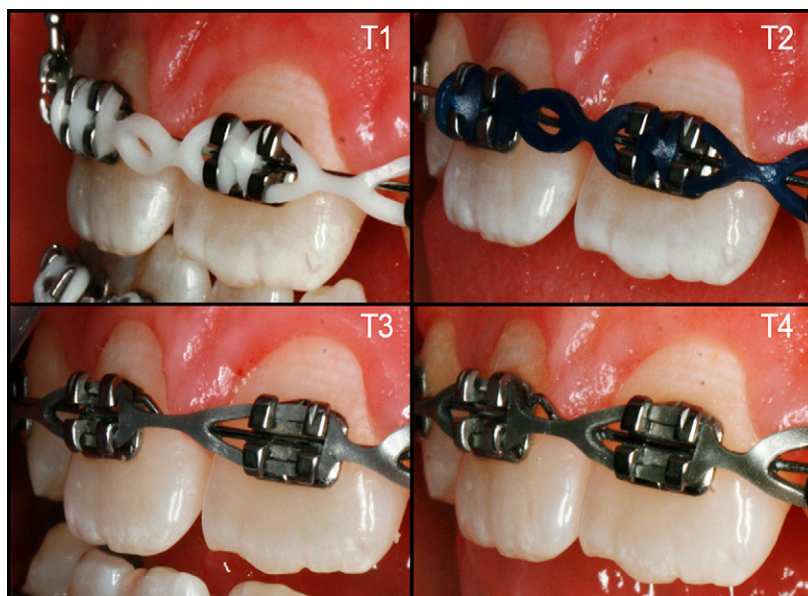


Fig 6. Intraoral photographs of the maxillary central incisors of a patient from T1 to T4 using the MI Paste Plus.

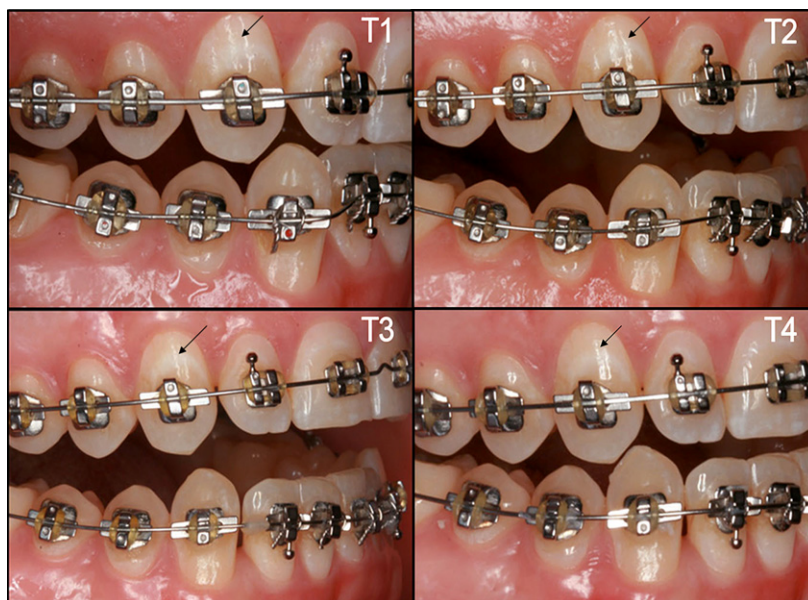


Fig 7. Right buccal intraoral photographs of a patient from T1 to T4 using the placebo. *Arrows* indicate changes in white spot lesion.

chance for the international caries detection and assessment system results to be significant.

Another interesting characteristic of this study was the effect of the paste on the location of lesions on the surfaces of the teeth. [Tables III and IV](#) show that the surface effect on the mean enamel decalcification index scores was highly significant. The distal surface in the MI Paste Plus

group showed the greatest percentage of decrease in decalcifications; in the placebo group, the distal and gingival surfaces showed the greatest percentages of increases in white spot formation. For the MI Paste Plus and the placebo, at every time point, the incisal edge average enamel decalcification index score differed significantly from the other surfaces (mesial, distal, and

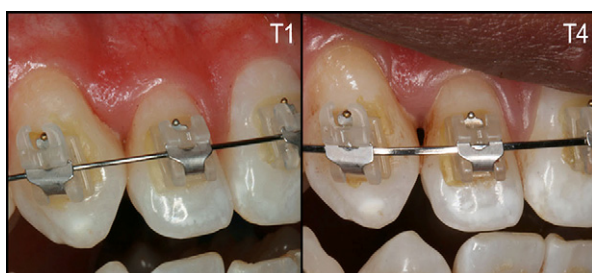


Fig 8. Intraoral photographs of the maxillary right central and lateral incisors and canine of a patient at T1 and T4 using the placebo.

gingival) individually. This showed a tendency, in this patient population, for incisal decalcifications. Perhaps this is a systematic error in the sample that the incisal edges in this patient population had more white spots on the incisal quadrant than the gingival quadrant, which is typically reported to be prone to the most decalcification. This systematic error was unlikely, though, since the results were independently obtained from 2 operators (M.A.R., J.T.N.), and intraoperator reliability was high. It is also shown in Figure 2 that after T1 the gingival surfaces of the MI Paste Plus sample had lower mean enamel decalcification index scores than did the gingival surfaces of the placebo group. This result suggested that the gingival portion of the tooth was particularly sensitive to orthodontic treatment during white spot lesion formation, especially in the placebo group. Furthermore, MI Paste Plus had an impact on reducing white spots on the gingival surfaces.

This clinical study had some limitations. One was that the patients' compliance could not be controlled, standardized, or measured. In addition, there was no standard delivery system for the MI Paste Plus, so the protocol of using the trays for 3 to 5 minutes per night was developed and chosen on the basis of the best clinical practice. In the future, compliance should be monitored and factored into the process somehow, and the study could be conducted after the brackets are debonded and gingival inflammation is at a minimum.

A more serious limitation was objectifying the scoring for the graders in scoring the enamel decalcification index and international caries detection and assessment system. The visual impact of decalcification can be somewhat different for each observer. However, great efforts were used to standardize and calibrate the operators. In addition, the intraobserver and interobserver variabilities were adequate. The most effective means of studying decalcification is to carry out a histosection of the enamel of the teeth, but this process would involve sacrificing teeth and precludes a clinical study with live subjects.

Table VI. ANOVA table for average international caries detection and assessment system scores

	P value	Power
Product	0.16	0.278
Time	0.92	0.079
Product/time interaction	0.06	0.609

Currently, more dental products are coming out with casein phosphopeptide-amorphous calcium phosphate, the active ingredient in MI Paste Plus. In the future, orthodontic bonding adhesives containing casein phosphopeptide-amorphous calcium phosphate could become popular. At present, the American Dental Association Foundation is developing biologically remineralizing composites, or "smart composites," that contain amorphous calcium phosphate. Even sports drinks are being developed that contain casein phosphopeptide-amorphous calcium phosphate. The possibilities for its applications are endless. It will, it seems, be a part of the future in orthodontists' fight against white spots and decalcification.

CONCLUSIONS

The following results can be drawn from this randomized controlled trial.

1. MI Paste Plus not only had a preventive action of white spot development during orthodontic treatment, but also decreased the number of white spot lesions.
2. The placebo had no preventive action on white spot development during orthodontic treatment; the number of lesions actually increased.
3. MI Paste Plus had an impact on reducing white spots on the gingival surfaces, whereas the placebo group had the opposite effect.
4. The incisal surface effect on mean enamel decalcification index scores over time and between products was highly significant in that the incisal enamel decalcification index scores were consistently higher than those of the other surfaces (mesial, distal, and gingival).

REFERENCES

1. Årtun J, Brobakken BO. Prevalence of carious white spots after orthodontic treatment with multibonded appliances. *Eur J Orthod* 1986;8:229-34.
2. Gwinnett AF, Ceen RF. Plaque distribution on bonded brackets: a scanning microscope study. *Am J Orthod* 1979;75:667-77.
3. Sakamaki ST, Bahn AN. Effect of orthodontic banding on localized oral lactobacilli. *J Dent Res* 1968;47:275-9.

4. O'Reilly MM, Featherstone JDB. Demineralization and remineralization around orthodontic appliances: an in vivo study. *Am J Orthod Dentofacial Orthop* 1987;92:33-40.
5. Ogaard B, Rolla G, Arends J. Orthodontic appliances and enamel demineralization. Part I: lesion development. *Am J Orthod Dentofacial Orthop* 1988;94:68-73.
6. Melrose CA, Appleton J, Lovius BBJ. A scanning electron microscopic study of early enamel caries formed in vivo beneath orthodontic bands. *Br J Orthod* 1996;23:43-7.
7. Mizrahi E. Enamel demineralization following orthodontic treatment. *Am J Orthod* 1982;82:62-7.
8. Gorelick L, Geiger AM, Gwinnett AJ. Incidence of white spot formation after bonding and banding. *Am J Orthod* 1982;81:93-8.
9. Banks PA, Burn A, O'Brien K. A clinical evaluation of the effectiveness of including fluoride into an orthodontic bonding adhesive. *Eur J Orthod* 1997;19:391-5.
10. Årtun J, Thylstrup A. Prevalence of carious white spots after orthodontic treatment with multibonded appliances. *Scand J Dent Res* 1986;94:193-201.
11. Marcusson A, Norevall LI, Persson M. White spot reduction when using glass ionomer cement for bonding in orthodontics: a longitudinal and comparative study. *Eur J Orthod* 1997;19:233-42.
12. Al-Khateeb S, Forsberg CM, de Josselin de Jong E, Angmar-Mansson B. A longitudinal laser fluorescence study of white spot lesions in orthodontic patients. *Am J Orthod Dentofacial Orthop* 1998;113:595-602.
13. Ogaard B, Rolla G, Arends J, ten Cate JM. Orthodontic appliances and enamel demineralization. Part II: prevention and treatment of lesions. *Am J Orthod Dentofacial Orthop* 1988;94:123-8.
14. Geiger AM, Gorelick L, Gwinnett AJ, Griswold PG. The effect of a fluoride program on white spot formation during orthodontic treatment. *Am J Orthod Dentofacial Orthop* 1988;93:29-37.
15. Geiger AM, Gorelick L, Gwinnett AJ, Benson BJ. Reducing white spot lesions in orthodontic populations with fluoride rinsing. *Am J Orthod Dentofacial Orthop* 1992;101:403-7.
16. Stratemann MW, Shannon IL. Control of decalcification in orthodontic patients by daily self-administered application of a water-free 0.4 percent stannous fluoride gel. *Am J Orthod* 1974;66:273-9.
17. Banks PA, Richmond S. Enamel sealants: A clinical evaluation of their value during fixed appliance therapy. *Eur J Orthod* 1994;16:19-25.
18. Wilson AD, Kent BE. The glass-ionomer cement: a new translucent filling material. *J Appl Chem Biotechnol* 1971;21:313.
19. Vorhies AB, Donly KJ, Staley RN, Wefel JS. Enamel demineralization adjacent to orthodontic brackets bonded with hybrid glass ionomer cements: an in vitro study. *Am J Orthod Dentofacial Orthop* 1998;114:668-74.
20. Underwood ML, Rawls HR, Zimmerman BF. Clinical evaluation of a fluoride-exchanging resin as an orthodontic adhesive. *Am J Orthod Dentofacial Orthop* 1989;96:93-9.
21. Basdra EK, Huber H, Komposch G. Fluoride release from orthodontic bonding agents alters enamel surface and inhibits enamel demineralization in vitro. *Am J Orthod Dentofacial Orthop* 1996;109:466-72.
22. Cain K, Hicks J, English J, Flaitz C, Powers J, Rives T. In vitro enamel caries formation and orthodontic bonding agents. *Am J Dent* 2006;19:187-92.
23. Angle EH. Treatment of malocclusion of the teeth. 7th ed. Philadelphia: S.S. White Dental Manufacturing; 1907.
24. Corbett JA, Brown LR, Keene HJ, Horton IM. Comparison of Streptococcus mutans concentrations in non-banded and banded orthodontic patients. *J Dent Res* 1981;60:1936-42.
25. Bloom RH, Brown LR. A study of the effects of orthodontic appliances on the oral microbial flora. *Oral Surg* 1964;17:658-67.
26. Balenseifen JW. Study of dental plaque in orthodontic patients. *J Dent Res* 1970;49:320-4.
27. Adams RJ. The effects of fixed orthodontic appliances on the cariogenicity, quantity and microscopic morphology of oral lactobacilli. *J Oral Med* 1967;22:88-98.
28. Lundstrom F, Krasse B. Streptococcus mutans and lactobacilli frequency in orthodontic patients; the effect of chlorhexidine treatments. *Eur J Orthod* 1987;9:109-16.
29. Darling AI. Studies of the early lesion of enamel caries with transmitted light, polarized light and radiography. Part 1. *Br Dent J* 1956;101:289-97.
30. Ogaard B. Prevalence of white spot lesions in 19-year-olds: a study on untreated and orthodontically treated persons 5 years after treatment. *Am J Orthod Dentofacial Orthop* 1989;96:423-7.
31. Zero DT. Dental caries process. *Dent Clin North Am* 1999;43:635-64.